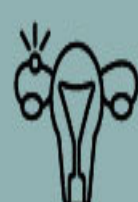


THE DIFFERENTIAL DIAGNOSIS OF CORPUS LUTEUM CYST

Condition

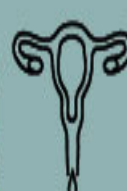Investigations & clinical findings



Ectopic pregnancy

1

Vaginal bleeding, HCG levels, tubal ring on ultrasound



Acute appendicitis

2

Pain, Digestive symptoms, Ultrasound, Blood tests



Cystitis

3

Urinary symptoms, Blood and urine tests



Adnexal masses

4

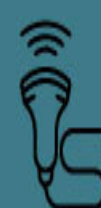Pain, Fullness, MRI, Blood tests



Adnexal torsion

5

Pain, Ultrasound, MRI



Pelvic inflammatory diseases & tubo-ovarian abscess

6

Fever, Pain, Blood tests, Ultrasound



References

1. Cross-sectional imaging of acute gynaecologic disorders: CT and MRI findings with differential diagnosis—part I: corpus luteum and haemorrhagic ovarian cysts, genital causes of haemoperitoneum and adnexal torsion; Springer Open
2. Hemorrhagic corpus luteum: Clinical management update; National Library of Medicine