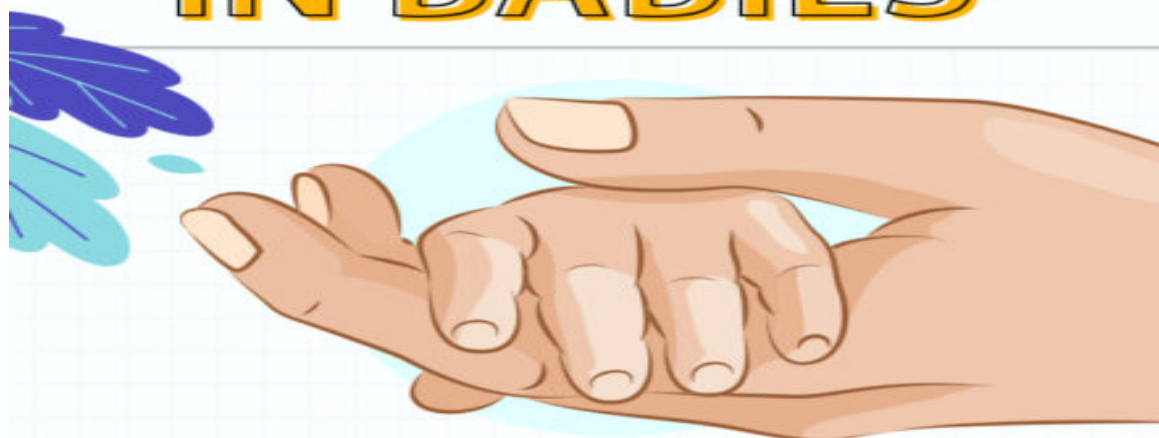

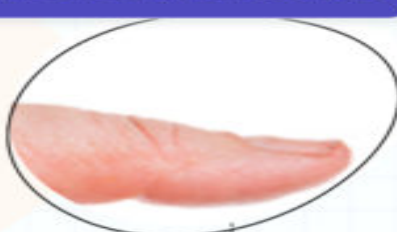NAIL ALTERATIONS IN BABIES



PHYSIOLOGICAL ALTERATIONS

KOILONYCHIA

- Nail surface is flat or concave (spooning)
- Resolves as nail plate thickens with age



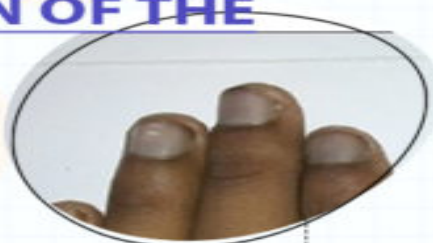ONYCHOSCHIZIA

- Splitting of the nails
- Usually caused by an injury
- Requires no specific treatment



PIGMENTATION OF THE NAIL FOLD

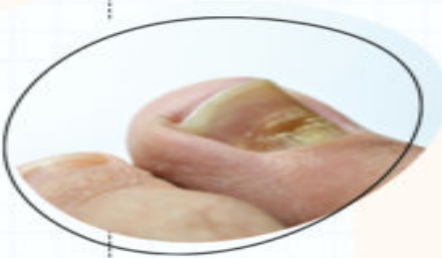
- The nail folds appear light brown or ochre
- Condition is harmless



Source: Indian Journal of Paediatric Dermatology

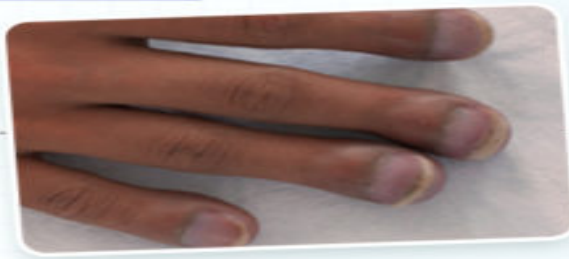BEAU'S LINES

- Side-to-side depression along a single line
- Caused by intrauterine distress or during birth
- Resolves in 14 weeks



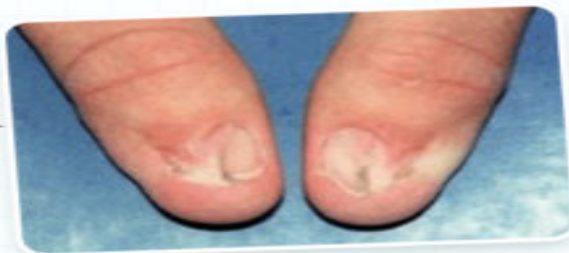PATHOLOGICAL ALTERATIONS

CLUBBING



- Fingertips enlarge, and the nails curve around them
- May occur due to congenital heart, lung, or intestinal disorders

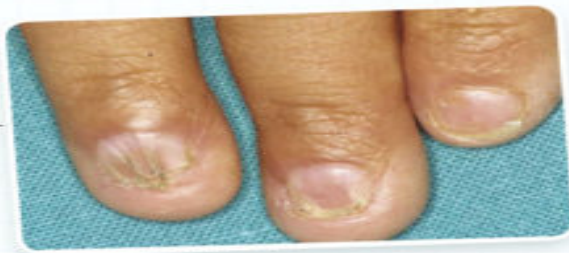NAIL-PATELLA SYNDROME



Source: MedLine Plus

- Autosomal dominant disorder
- Causes abnormalities in nails, knees, and elbows
- Underdeveloped triangular nails

NAIL-PATELLA SYNDROME



Source: ACTAS Dermo

- Congenital disorder
- Chalky buildup under the nails
- Small, thin, and brittle nails

References

- 1 Disorders of nail in infants and children; Indian Journal of Paediatric Dermatology
- 2 Nail Disorders in Children; Karger